



RESENTING CLINICAL SIGNS

History: Pre-dental thoracic radiographs revealed an enlarged cardiac silhouette and tracheal narrowing. No murmur.

DATE

7/1/22

ECHOCARDIOGRAPHIC FINDINGS

2D, M-mode, and Doppler study.

PERFORMED BY:

Amy Mayhew, LVT

INTERPRETED BY

Keith Blass, DVM,
MS, DACVIM
(Cardiology)

Left atrial size is normal. The mitral valve appears normal, though trace mitral regurgitation is present. Left ventricular dimensions are normal. Left ventricular systolic function is normal. The aorta and aortic valve are normal. Right atrial and right ventricular dimensions are normal. The tricuspid valve is normal. The pulmonary artery and pulmonic valve are normal. No shunting lesions are visualized. No pericardial effusion or cardiac masses are seen.

PATIENT

Widget Salmons

LA - 23.0 mm
LVIDd - 24.4 mm
LVIDs - 15.1 mm
FS - 38%
RA - 20.0 mm
LVOT - 1.43 m/s
RVOT - 1.00 m/s

ASSESSMENT/RECOMMENDATIONS

Normal echocardiogram

SPECIES

Canine

This examination demonstrates no evidence of structural heart disease, as trace mitral regurgitation can be considered a normal physiologic variant. As such, the cardiomegaly noted in Widget's radiograph is very likely a normal variant, as no evidence of cardiac chamber enlargement is present in her echocardiogram.

BREED

Pomeranian

Widget's cardiovascular risk for general anesthesia is low based on this exam, and there are no contraindications to the use of any specific anesthetic agents.

No therapy is recommended based on this exam.

SEX

FS

A recheck echocardiogram is recommended if Widget develops a murmur, or if other new physical exam and/or clinical abnormalities compatible with cardiac dysfunction develop.

AGE

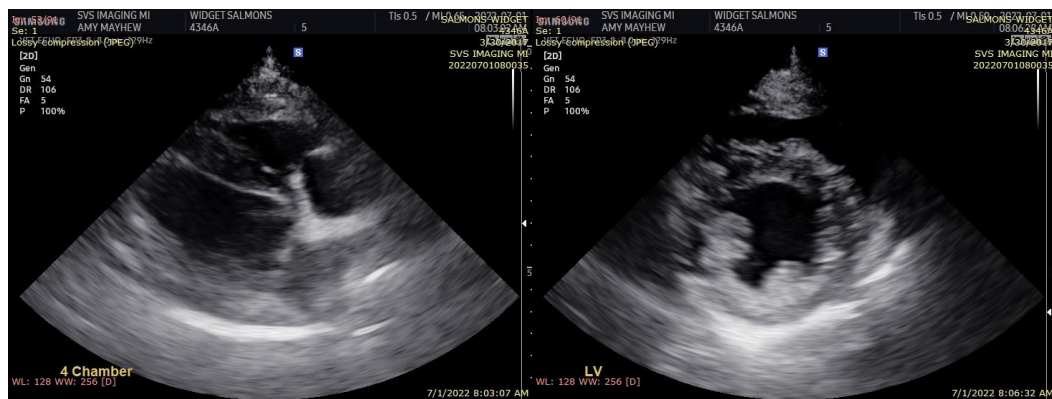
5 y

WEIGHT

17.8 lb

HOSPITAL NAME

SVS Imaging MI



REFERRING VET

Family Vet Practice

The information and recommendations provided are based on the images presented by the



referring veterinarian. No evaluation can be communicated regarding pathology that was not visible in the image/video clips provided.

DATE

7/1/22

Thank you for this referral. If the clinical or image interpretation does not parallel your findings or if I can be of any further assistance please contact me.

PERFORMED BY: Keith Blass, DVM, MS, DACVIM (Cardiology)

KeithBlass@gmail.com
631-804-5754

Amy Mayhew, LVT

INTERPRETED BY

Keith Blass, DVM,
MS, DACVIM
(Cardiology)

PATIENT

Widget Salmons

SPECIES

Canine

BREED

Pomeranian

SEX

FS

AGE

5 y

WEIGHT

17.8 lb

HOSPITAL NAME

SVS Imaging MI

REFERRING VET

Family Vet Practice